

Cadaveric observation of an uncommon Inter-tendinous slip in the Extensor Carpi Radialis complex

¹Jayalakshmi B, ^{2*}Mital Kanani and ³B G Kulkarni

^{1,2*}Department of Rachana Sharir, Parul Institute of Ayurved and Research, Parul University, Vadodara - 391760 (India)

³Parul Institute of Ayurved and Research, Parul University, Vadodara - 391760 (India)

Corresponding author: Dr. Mital Kanani* Assistant Professor, Department of Rachana Sharir, Parul Institute of Ayurved and Research, Parul University, Vadodara - 391760 (India), Ph No.: 8758072340
Email ID: mital.kanani11@gmail.com

Abstract

The extensor carpi radialis longus (ECRL) and brevis (ECRB) muscles play a fundamental role in the extension and abduction of the wrist. Although isolated anatomical deviations are documented, the literature currently lacks a cohesive classification system and a comprehensive analysis of the collective clinical significance of these variations. A precise anatomical dissection was conducted on the right upper extremity of a cadaveric specimen. The study focused on identifying the morphological and tendinous arrangements of the radial extensor group. Investigations uncovered a rare structural anomaly consisting of a distinct inter-tendinous bridge linking the ECRL and ECRB tendons. Reporting these inter-tendinous connections is vital for medical literature. Identifying such anatomical diversity is essential for clinicians to ensure diagnostic precision, optimize preoperative planning, and improve surgical results in orthopaedic and musculoskeletal interventions.

Key words : Extensor carpi radialis longus, Extensor carpi radialis brevis, Anatomical variations, Inter-tendinous Slip.

Anatomical variations hold significant importance in medical practice for the surgical planning, recognizing these variations is crucial as it helps surgeons avoid damaging vital vessels or nerves during operations, thereby reducing complications and improving patient outcomes.² In diagnostic imaging, anatomical variations can sometimes resemble pathological

¹M.D. Scholar, ^{2*} Assistant Professor, ³Principal,

conditions, so understanding and identifying them correctly prevents misdiagnosis and unnecessary treatments. Additionally, certain variations may lead to clinical conditions such as nerve compression syndromes or influence blood supply, affecting disease risk and symptoms. Therefore, comprehending these variations is essential in medical education and practice to minimize errors and enhance patient care.¹⁰

The extensor carpi radialis longus (ECRL) and extensor carpi radialis brevis (ECRB) are the muscles in the posterior compartment of the forearm involved in wrist extension and hand abduction. The ECRL originates from the lateral supracondylar ridge of the humerus, while the ECRB arises from the lateral epicondyle of the humerus via the common extensor tendon. Both muscles course down the forearm, passing beneath the extensor retinaculum in the second dorsal compartment within a common synovial sheath. The ECRL inserts onto the base of the second metacarpal, and the ECRB attaches to the base of the third metacarpal. Nerve supply to the ECRL is from the radial nerve (C6-C7), whereas the ECRB receives innervation from the deep branch of the radial nerve, also known as the posterior interosseous nerve (C7-C8). These muscles work together to extend the wrist and abduct the hand, playing an important role in wrist stability and function during grip and hand movements.³

Although many studies talk about anatomical variations, most of them discuss only one variation at a time. In this study, comparison of different variations and explains their clinical importance together. When the information is scattered, making it difficult for doctors to apply this knowledge while planning

surgeries, diagnosing patients, or teaching medical students. Therefore, there is a strong need for a review that brings all these variations together and explains their clinical importance in one place. This article is written to fill that gap by summarizing common anatomical variations and their practical uses, helping doctors make better decisions and improving patient care.

Review of Extensor Carpi Radialis Variations :

Variations in the extensor carpi radialis muscles refer to differences in their structure, number, origin, insertion, or course compared to the typical anatomy described in textbooks.

Accessory Muscles: The Extensor Carpi Radialis Intermedius (ECRI) is one such accessory muscle. It is an additional muscle belly that appears between the two main extensor carpi radialis muscles—the longus (ECRL) and brevis (ECRB). This muscle typically attaches to the bases of the second or third metacarpal bones in the hand, which are the bones connected to the index and middle fingers.

The Extensor Carpi Radialis Accessorius (ECRA) is an even rarer accessory muscle. It can start from either the ECRL or ECRB muscle and has variable insertion points. It may connect to the first metacarpal bone (linked to the thumb), to a thumb muscle called the abductor pollicis brevis, or to the first dorsal interosseous muscle, which is involved in finger movement⁵.

Accessory tendons : Accessory tendons are extra tendon fibers that are not

usually found but sometimes exist alongside the main tendons of the extensor carpi radialis longus (ECRL) and extensor carpi radialis brevis (ECRB) muscles. These accessory tendons can connect the tendons of the ECRL and ECRB muscles or may arise as additional small slips from one of these muscles. They differ in size—some may be thin and small, while others can be thicker—and their paths (course) along the forearm and wrist also vary. These accessory tendons can affect how the muscles function and may be important during surgeries or when interpreting medical images to avoid confusion with injuries or abnormal structures.⁷

Unusual Insertions : Unusual insertions of the extensor carpi radialis (ECR) tendons represent anatomical variations where the tendons attach to bones or structures different from their typical sites. Normally, the extensor carpi radialis longus (ECRL) inserts onto the base of the second metacarpal, and the extensor carpi radialis brevis (ECRB) attaches to the base of the third metacarpal. However, in some cases, these tendons may insert onto the first metacarpal, which is usually the attachment site for muscles acting on the thumb. Such atypical insertions can also include accessory slips that merge into tendons of neighbouring muscles, like the abductor pollicis brevis or other thumb muscles.⁴

These unusual insertions may alter the mechanical action of the muscles, potentially affecting wrist and thumb movement, and can have clinical consequences during surgical interventions or when interpreting imaging studies. Identifying these variations is crucial to avoid surgical complications or diagnostic errors, as these atypical attachments might be

mistaken for pathological findings or contribute to unexplained wrist or hand dysfunction⁹.

Tendinous Connections : Tendinous connections between the extensor carpi radialis longus (ECRL) and extensor carpi radialis brevis (ECRB) represent an unusual anatomical variation characterized by an inter-tendinous slip or band linking the two tendons. This type of tendinous communication is relatively rare and suggests a form of structural integration that may influence the coordinated function of these muscles. In the specific case observed, the inter-tendinous slip serves as a direct connection between the ECRB and ECRL tendons along their course in the forearm or wrist. This connection may affect the biomechanics of wrist extension by enabling a more synchronized contraction or force distribution between these two muscles. From a clinical perspective, recognizing this tendinous slip is critical as it can present challenges during surgical procedures, tendon repair, or reconstruction, and may also cause confusion during diagnostic imaging if mistaken for pathological adhesions or tears¹¹.

Neurovascular Variations :

Nerve Supply : Normally, the extensor carpi radialis longus (ECRL) is innervated by the radial nerve (C6-C7), while the extensor carpi radialis brevis (ECRB) receives its motor innervation primarily from the deep branch of the radial nerve, also called the posterior interosseous nerve (C7-C8). However, anatomical studies have documented variations where the ECRB may receive direct innervation from the superficial branch of the radial nerve, which is typically regarded as a purely sensory nerve¹. This variation is highly

significant for surgeons because accidental injury or transection of the superficial radial nerve during procedures could lead to unexpected motor deficits, such as weakness in wrist extension, rather than just sensory loss as traditionally expected.⁸

Case report of inter-tendinous slip :

During routine dissection of the right upper limb of a female adult cadaver, an unusual anatomical variation was identified between the extensor carpi radialis longus (ECRL) and extensor carpi radialis brevis (ECRB) muscles. Upon careful removal of the skin and subcutaneous tissues over the posterior forearm and wrist, the extensor compartment was fully exposed. The extensor retinaculum was initially preserved to maintain the integrity of the tendon sheath and then delicately incised to allow detailed visualization of the tendons passing beneath it. An accessory tendinous slip bridging the ECRL and ECRB was observed (Fig. 1 & 2). Detailed examination of this tendinous slip was performed, noting its origin, course, and insertion. Measurements of length and width were accurately recorded using measuring tapes and photographs were obtained for documentation and comparison.

Observations :

Tendon of extensor carpi radialis brevis (ECRB) inserted into the base of the third metacarpal bone; tendon of extensor carpi radialis longus (ECRL) inserted into the base of the second metacarpal bone. Note that the upward arrows given in Fig 1 indicate the course of the inter-tendinous slip in between the ECRL & ECRB. The length of inter-tendinous slip was found 10.5 cm (Fig. 2).

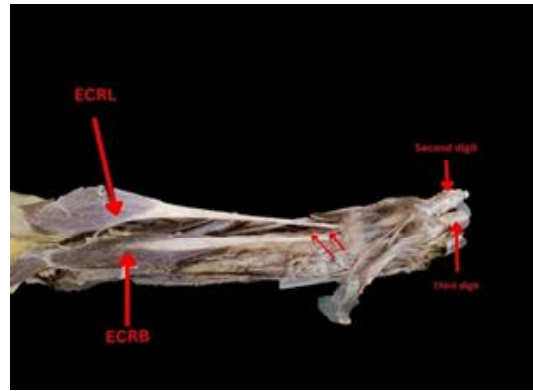


Fig. 1. Extensor compartment of the right forearm and hand region.

Legend-Figure [1]. Posterior view of the right forearm and hand demonstrating an intertendinous slip. The extensor compartment has been dissected to reveal a variant muscular/tendinous connection (arrow) originating from the extensor carpi radialis longus (ECRL) and inserting into the tendon of the extensor carpi radialis brevis (ECRB). Note the insertion points of the ECRL and ECRB on the second and third metacarpal bases, respectively.

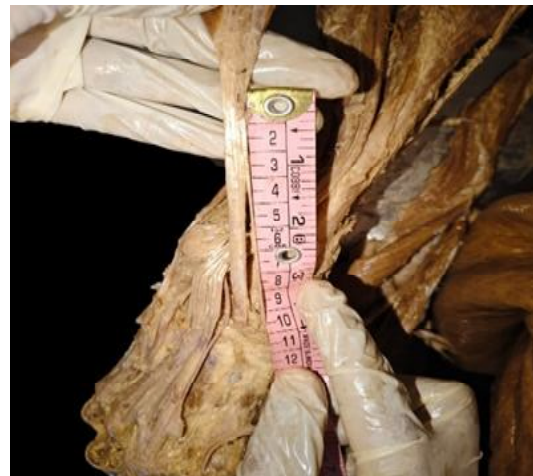

Fig. 2. The length of inter-tendinous slip

Legend-Figure 2. Anatomical variation of the radial extensors. Close-up view of the right extensor compartment highlighting an intertendinous slip. The slip measures 10.5 cm in length, representing a significant communicating bridge between the ECRL and ECRB.

The embryological basis for the presence of an accessory tendinous slip connecting the extensor carpi radialis longus (ECRL) and extensor carpi radialis brevis (ECRB) muscles likely stems from variations in the differentiation and splitting of muscle masses during limb development. During embryogenesis, the muscles of the forearm develop from a common mesenchymal muscle mass in the limb bud. This mass undergoes segmentation and differentiation into individual muscle groups through complex processes of cellular proliferation, migration, and programmed cell death (apoptosis). Accessory tendinous slips may result from incomplete separation or fusion between adjacent muscle primordia, causing residual connections to persist between muscles that typically become distinct entities. Specifically, for the ECRL and ECRB, incomplete cleavage of their common extensor mass or retention of bridging muscle fibres and tendinous tissue during development may explain the formation of an interconnecting tendon. Such variations are considered normal variants arising from developmental plasticity and are not usually pathological but can influence muscle function and anatomical relationships in adulthood.⁶

Lateral Epicondylalgia, commonly known as Tennis Elbow, is characterized by discomfort around the outer part of the elbow, particularly near the lateral epicondyle of the humerus, and is often triggered by repetitive

stress on the wrist extensor muscles. Among these, the Extensor Carpi Radialis Longus (ECRL) and Extensor Carpi Radialis Brevis (ECRB) play a major role and are frequently associated with pain and functional impairment seen in this condition.⁴

The anatomical variations of the extensor carpi radialis (ECR) muscles, though often considered rare, hold significant clinical importance. Our detailed morphological report of a unique inter-tendinous slip connecting the ECRL and ECRB tendons, combined with a comprehensive review of all known ECR variations, underscores a crucial need for a more integrated understanding of anatomical diversity. This study demonstrates that these variations are not merely academic curiosities but can directly influence muscle biomechanics, affect diagnostic imaging, and introduce critical considerations for surgical planning.

The presence of accessory tendons, split insertions, or neurovascular anomalies can alter normal function and may be a source of unexplained wrist pain or dysfunction. For the surgeon, recognizing these variations is vital to prevent iatrogenic injury to nerves and vessels, while for the radiologist, this knowledge is key to avoiding misdiagnosis. Ultimately, this integrated knowledge base enhances patient care by promoting more informed decision-making in both diagnostic and therapeutic settings. Continued anatomical study, particularly with a focus on documenting and classifying such variations, remains essential to bridging the gap between theoretical knowledge and practical application, ensuring that clinicians are prepared for the full spectrum of human anatomy they encounter.

References :

1. Alraddadi A. (2021). *Cureus*. May 3; 13(5): e14818. doi:10.7759/cureus.14818. PMID: 33996311; PMCID: PMC8117423.
2. Buckingham M, L Bajard, T Chang, P Daubas, J Hadchouel, S Meilhac, D Montarras, D Rocancourt, and F. Relaix (2003). *J Anat*. 2003 Jan; 202 (1): 59–68. doi:10.1046/j.1469-7580.2003.00139.x. PMID: 12587921; PMCID: PMC1571050.
3. Chaurasia BD. (2013). *Human Anatomy: Volume 1 – Upper Limb and Thorax*. 6th ed. New Delhi: CBS Publishers & Distributors; p. 134.
4. Coello MA, LA Coomar, and M.A Campbell (2024). *J Funct Morphol Kinesiol*. 9(3): 109. doi:10.3390/jfmk9030109. PMID: 39051270; PMCID: PMC11270274.
5. Nayak SR, A Krishnamurthy, LV Prabhu, R Rai, AV Ranade, and S. Madhyastha (2008). *Clinics (Sao Paulo)*. 63(1): 85–90. doi:10.1590/s1807-59322008000100015. PMID: 18297212; PMCID: PMC2664178.
6. Nurul Huda MN, AA San, and F. Othman (2014). *Int J Morphol*. 32(1): 29–31.
7. Riek S, RG Carson, and A. Wright (2000). *J Electromyogr Kinesiol*. 10(4): 249–253. doi:10.1016/S1050-6411(00)00017-1.
8. Sanudo JR, R Vázquez, and J. Puerta (2019). *Eur J Anat*. 7: 1–3. Available from: <https://www.eurjanat.com/v1/data/pdf/eja.03S10001.pdf>
9. Sawyer FK, JJ Stefanik, and R S. Lufner (2020). *Diagnostics (Basel)*. Jun 2; 10(6): 366. doi:10.3390/diagnostics10060366. PMID: 32498404; PMCID: PMC7345276.
10. West CT, D Ricketts, and C. Brassett (2017). *Folia Morphol (Warsz)*. 76(4): 742–747. doi:10.5603/FM.a2017.0047.
11. Young RC, JR Sañudo, RM Mirapeix, and P. Abrahams (1998). *Eur J Anat*. 2(1): 1–84.